

Closed Book

Questions related to the guide lines

QUESTION # 1

Which of the following would be first-line therapy for sialorrhoea in Amyotrophic Lateral Sclerosis, according to EFNS guidelines (2012)?

- A: Botulin toxin into the salivary glands.
- B: Irradiation of salivary glands.
- C: Submandibular duct transposition.
- D: Transdermal hyoscine.**
- E: Oral trihexiphenidyl

QUESTION # 2

Which of the following has been recommended to be performed every 6 months in a patient with definite amyotrophic lateral sclerosis, according to the EFNS guidelines (2012).

- A : Expiratory peak flow.
- B : Mini Mental State Examination.
- C : Serum albumin.
- D : Assessment of speech function.**
- E : Chest X-ray.

QUESTION # 3

In which of the following regions of the world is dentatorubral-pallidoluysian-atrophy (DRPLA) most prevalent?

- A: Africa
- B: Asia.**
- C: Australia
- D: Europe
- E: South America.

QUESTION # 4

Which of the following diseases is most likely given the finding of 14-3-3 in the CSF?

- A: Amyotrophic lateral sclerosis
- B: Alzheimer's disease.
- C: CreutzfeldtJakob disease.**
- D: Frontotemporal dementia.
- E: Progressive supranuclear palsy.

QUESTION # 5

Which of the following imaging techniques is useful to distinguish between the various Parkinsonism-Dementia Syndromes?

- A: Diffusion –tensor Imaging (DTI) MRI.
- B: Diffusion Weighted Image (DWI) MRI.
- C: Fluid-attenuated inversion recovery (FLAIR) MRI.
- D: SPECT perfusion imaging.
- E: T1-weighted MRI with gadolinium**

.

QUESTION # 6

Which of the following is in the exclusion-criteria for Parkinson’s disease, according to the EFNS-Guideline (2013)?

- A: Hyposmia.
- B: Severe L-dopa-induced chorea.
- C: Strictly unilateral involvement after 3 years.**
- D: Symmetric presentation of symptoms.
- E : Visual hallucinations.

QUESTION # 7

Which of the following test is most sensitive for the diagnosis ocular myasthenia gravis?

- A: AChR antibody detection.
- B: The edrophonium test.
- C: The ice-pack test.
- D: Repetitive stimulation of a cranial nerve.
- E: Single fibre EMG of a facial muscle.**

QUESTION # 8

For which of the following anti-epileptic drugs is there some evidence of effectiveness in the treatment of primary restless legs syndrome?

- A: Lamotrigine.
- B: Levetiracetam.
- C: Oxcarbazepine
- D: Phenytoin.
- E: Pregablin.**

QUESTION # 9

Which of the following non-pharmaceutical therapies has some effectiveness in the short-term treatment of restless legs syndrome?

- A: Aerobic training.
- B: Infrared light therapy.
- C: Physiotherapy.
- D: Yoga.
- E: None of the above**

.

QUESTION # 10

Which of the following statements with regard to Polymerase Chain Reaction (PCR) in the diagnosis of viral CNS infections is most valid?

- A: Due to technical restrictions only one virus within one CSF sample can be detected.
- B: Adequate specimen storage is important for optimal reliability of this test.**
- C: The sensitivity of a PCR for Herpes Simplex Encephalitis decreases after 3 days.
- D: The specificity of a PCR for viral CNS diseases generally is lower than 80%.
- E: Nowadays with PCR, brain biopsy for the diagnosis of progressive multifocal leukoencephalopathy (PML) is obsolete.

QUESTION # 11

Which of the following is the most prominent effect of pallidotomy in Parkinson's disease?

- A: Reduction of bradykinesia.
- B: Reduction of dyskinesia.**
- C: Reduction of freezing.
- D: Reduction of rigidity.
- E: Reduction of tremor.

QUESTION # 12

Which drug is recommended in the EFNS guidelines as first line treatment for convulsive status epilepticus in an adult person?

- A: Diazepam.
- B: Levetiracetam.
- C: Lorazepam.**
- D: Phenytoin.
- E: Valproate.

Closed book

General questions

QUESTION # 1

What kind of identification inability does prosopagnosia reflect?

- A: Facial expression.
- B: Familiar faces.**
- C: Melody in language.
- D: Non-musical sounds.
- E: Pitch of a melody.

QUESTION # 2

Which of the following symptoms is found with increased frequency in patients with neuropathic pain as compared with patients with nociceptive pain ?

- A: Deep aching pain.
- B: Lancing pain.
- C: Pain evoked by local pressure.
- D: Pain on exercise.
- E: Sensation of pins and needles.**

QUESTION # 3

What do laser evoked potentials mainly assess in patients with neuropathic pain?

- A: The autonomous reflex loop.
- B: The function of lemniscal pathway.
- C: The function of spinothalamic pathway.**
- D: The function of spinal interneurons.
- E: The interaction between lemniscal and spinothalamic pathway.

QUESTION # 4

Which of the following drugs is recommended as the first line treatment of painful diabetic neuropathy?

- A: Alpha1 blockers.
- B: Chloride channel inhibitors.
- C: Dopaminergic agents.
- D: Serotonergic agents.**
- E: GABA-antagonists.

QUESTION # 5

Which is the most common skeletal deformity associated with Charcot-Marie-Tooth disease

- A: Pes cavus (high arched foot)**
- B: Pes equinus (horse foot)
- C: Pes equinovarus (club foot)
- D: Pes planus (flat foot)
- E: Pes valgus (skew foot)

QUESTION # 6

Which of the following drugs is the most effective in preventing attacks in Menière's disease ?

- A: A glutamate antagonist.
- B: A histaminergic drug.**
- C: A potassium-channel blocker.
- D: A serotonergic drug.
- E: A sodium-channel blocker.

QUESTION # 7

Which of the following signs/syndromes is most likely to occur in a carotid artery dissection?

- A: Adie syndrome (tonic pupil).
- B: Argyll Robertson pupil (pupillary dysfunction with near-light dissociation).
- C: Horner's syndrome (ptosis and miosis).**
- D: Marcus-Gunn pupil (relative afferent pupillary defect).
- E: Parinaud syndrome (Vertical eye movement restriction with pupillary dysfunction).

QUESTION # 8

What is the correct term when a patient reports the experience of colours when hearing sounds?

- A: Dysaesthesia.
- B: Hyperaesthesia.
- C: Paraesthesia.
- D: Polyaesthesia.
- E: Synaesthesia.**

QUESTION # 9

A bedbound and thin 81 year old female presented with footdrop (weakened dorsiflexion and eversion of the foot). During the examination she also had sensory deficit in the anterolateral aspect of the lower leg and the dorsum of the foot including the web space between the 1st and 2nd metatarsals. Hip abduction by the gluteus medius was unaffected.

Which nerve is most likely to be affected?

A: The femoral nerve.

B: The peroneal nerve.

C: The posterior tibial nerve.

D: The saphenous nerve.

E: The sciatic nerve.

QUESTION # 10

Which of the following statements relating to torticollis (cervical dystonia) is correct ?

A: Torticollis is the most common form of focal dystonia.

B: Torticollis is most common in men.

C: Torticollis in young women is mostly associated with an autoimmune disease.

D: The first line treatment of torticollis is an anticholinergic drugs.

E: Torticollis is most often associated with an isolated genetic mutation.

QUESTION # 11

Which one of the following statements is most valid for primary torsion dystonia (PTD)?

A: PTD mostly starts after the age of 40 years.

B: PTD can successfully be treated with botulinum toxin.

C: PTD can successfully be treated with subthalamic nucleus deep brain stimulation.

D: A cerebral MRI shows no abnormalities specific to PTD.

E: More than half of the patients with PTD show pyramidal signs.

QUESTION # 12

Which of the following signs is a feature of progressive supranuclear palsy (PSP)?

A: Atrophy of the tongue.

B: Broad based gait.

C: Extensor plantar responses.

D: Miosis.

E: Spastic hypernasal speech.

QUESTION # 13

Which of the following structures undergoes degeneration that leads to neuropathic symptoms in Friedreich's ataxia?

A: Anterior roots.

B: Dorsal root ganglia.

C: Posterior columns.

D: Posterior roots.

E: Spinocerebellar tracts.

QUESTION # 14

In which region of the cortex is alpha-activity most prominent in an EEG done with the eyes closed?

A: Central.

B: Frontal.

C: Occipital.

D: Parietal.

E: Temporal.

QUESTION # 15

Which component of somatosensory evoked potentials indicates radicular-medullary damage?

A: N13.

B: P40.

C: N70.

D: P100.

E: P300

QUESTION # 16

Which of the following drugs should be chosen preferentially for treating vestibular paroxysmia due to vascular compression of the vestibular nerve?

A: Acetazolamide (Carbo-Anhydrase-Inhibitor)

B: Aminopyridine (Potassium Channel Blocker)

C: Baclofen (GABA-ergic Drug)

D: Carbamazepine (Sodium Channel Blocker)

E: Diazepam (Chloride Channel Activator)

QUESTION # 17

Where do the cholinergic neurons of the nucleus basalis Meynert mainly project to?

- A: Corpus pineale.
- B: Frontal neocortex.**
- C: Nucleus subthalamicus.
- D: Putamen.
- E: Thalamus.

QUESTION # 18

What does gadolinium enhancement reflect in patients with MS?

- A: Active antigen presentation.
- B: Acute axonal damage.
- C: Blood brain barrier permeability abnormalities.**
- D: Presence of macrophages.
- E: Vanishing white matter.

QUESTION # 19

What can be measured using proton MR spectroscopy?

- A: Axonal density
- B: The molecular composition of tissue.**
- C: The relative proportions of free and bound water.
- D: Tissue anisotropy.
- E: Water molecular motion and tissue anisotropy.

QUESTION # 20

What does the cerebrospinal fluid (CSF) albumin / serum albumin ratio reflect?

- A: Total protein content.
- B: Cerebrospinal fluid density.
- C: Blood-brain barrier status.**
- D: Neurodegeneration.
- E: Immunological status

QUESTION # 21

Which of the following is a direct MRI-sign of a sagittal sinus thrombosis?

- A: Haemorrhagic and non haemorrhagic infarcts.
- B: Generalized brain oedema.
- C: An empty delta sign.**
- D: Intense contrast enhancement of the tentorium cerebelli.
- E: Intense contrast enhancement of the falxcerebri.

QUESTION # 22

Which of the following is the commonest sign following an infarction of the lateral medulla oblongata?

A: Chewing weakness.

B: Hiccup.

C: Internuclearophthalmoplegia.

D: Unilateral loss of deep sensation.

E: Vertical gaze paralysis.

QUESTION # 23

Which of the following signs is most likely to occur in autosomal dominant spastic paraplegia with a SPG4-mutation?

- A: Amyotrophy.
- B: Diminished pain sensation.
- C: Dry skin due to autonomic dysfunction.

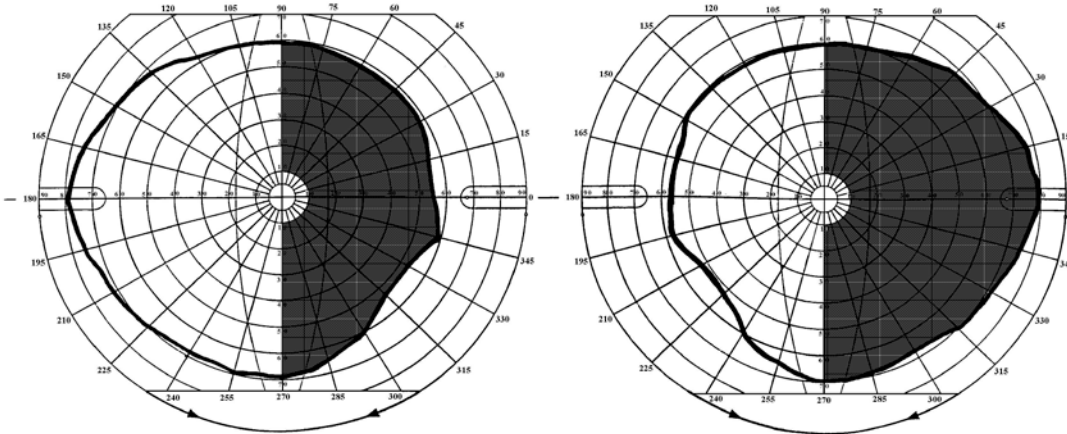
D: Reduced vibration sensation.

QUESTION # 24

Which of the following statements concerning neuromyotonia (NM) is most valid?

- A: NM is predominantly an inherited disease.
 - B: NM may be a paraneoplastic disease.**
 - C: NM is associated with rheumatoid disorders.
 - D: NM is associated with thyroid dysfunction.
- E: NM may occur in serum electrolyte disturbance.

QUESTION # 25



Which is the most likely occluded artery in a patient showing this visual defect?

- A: Carotid artery.
- B: Choroid artery.
- C: Medial cerebral artery.
- D: Posterior cerebral artery.**
- E: Thalamic artery.

QUESTION # 26

Which of the following EMG techniques measures the function of the neuromuscular junction most reliably?

- A: Macro EMG.
- B: Quantitative EMG.
- C: Single fibre EMG.**
- D: Small sample EMG.
- E: Surface EMG.

QUESTION # 27

What is the approximate speed of peripheral nerve regeneration?

- A : 2 mm per day.**
- B: 5 mm per day.
- C: 2 mm per week.
- D: 1 mm per week.

QUESTION # 28

What is the origin of the main contingent of afferent fibres to the dentate gyrus?

- A: Area striata.
- B: Entorhinal cortex.**
- C: Putamen.
- D: Supplementary motor cortex.
- E: Thalamus.

QUESTION # 29

Which of the following statements is most valid for acute onset hemi-ballismus?

- A: Hemi-ballismus can be effectively treated with dopamine antagonist drugs.**
- B: Hemi-ballismus mostly becomes bilateral at a late stage.
- C: Hemi-ballismus may be the result of an acute lesion of the dorsal thalamic nuclei.
- D: Hemi-ballismus symptoms mostly worsen by attempts to move.
- E: Hemi-ballismus nearly always occurs as an isolated symptom.

QUESTION # 30

Which of the following statements relating to treatment of Huntington's disease is most valid?

- A: Cholinesterase inhibitors have been shown to be effective in treating dementia.
- B: The dopamine depletortetrabenazine is useful in ameliorating chorea.**
- C: The glutamate release inhibitor Riluzole slows disease progression.
- D: Neuroleptic drugs worsen symptoms.
- E: Selective serotonin reuptake inhibitors should be avoided.

Open book questions

QUESTION #1

A 27 year old female complains of intermittent binocular diplopia for over one year. There is some asymmetric drooping of both eyelids. Double vision is apparent on awakening and subsides after about half an hour. In the late afternoon it may reappear and driving a car in the dark is not possible anymore. There are no further complaints. Her mother has experienced similar problems for a couple of years. She was diagnosed with a thyroid disorder.

On examination there is slight skew deviation with looking upward, after 10 seconds of sustained looking to the right, the left eye drifts to the midline whilst the right eye shows some horizontal jerky laterally directed movements. There is ptosis on the left; with passive elevation, the right eyelid starts drooping. There is no pupillary involvement. Repetitive nerve stimulation (3/sec, orbicularis oculi and abductor digiti V muscle) normal, anti AChR-antibodies negative. Needle EMG of the facial muscles, adductor pollicis and quadriceps muscle is normal.

Which diagnosis most likely explains the clinical features of this patient ?

- A : Lambert Eaton myasthenic syndrome
- B : Mitochondrial myopathy
- C : Multiple sclerosis
- D : Myasthenia gravis**
- E : Thyroid myopathy

QUESTION #2

A 62 year old female has swallowing problems and a hoarse voice. She states that the problem started suddenly 6 months ago after choking on a cup of coffee. She was not able to regain her voice that day, and although this improved, she was not able to produce a clear voice. She had lost 10 kg in weight but her body mass index remains considerable. She has been taking steroids for 2 years because of polymyalgia rheumatica. On clinical examination there is a left-sided atrophy of her tongue with some involuntary intramuscular movements at the left-side edge. She is not able to protrude her tongue into her right cheek, but is reasonable on the left side. The masseter reflex is completely absent; the pharyngeal reflex is normal on both sides. Her speech is slurred and has a hoarse quality. No other abnormalities were found on the remainder of the neurological examination.

Which diagnosis most likely explains the clinical features of this patient ?

- A ALS type of motor neurone disease.
- B Carotid dissection.
- C Myositis
- D Pharyngeal tumor.**
- E Progressive supranuclear palsy.

QUESTION #3

A 51-year-old male, with a history of herpetic shingles in dermatomes T7-10 three years ago complains about pain in the back side of his right leg. He mentioned that there has been some red discoloration of the skin on his right lower leg, but definitely no shingles.

On physical examination, he demonstrated normal tone and full strength in all muscle groups bilaterally; reflexes were normal apart from the knee-reflex being somewhat decreased on the right; the adductor reflexes were symmetric. MRI of the lumbar spine showed degenerative disc disease at all lumbar levels, with slight bilateral foraminal stenosis at L3 and L4, but no herniated disc. Results of an electromyogram were normal. His cerebrospinal fluid showed a predominantly lymphocytic pleocytosis(110 cells/L), a raised protein level (570mg/L) and intrathecal Ig-synthesis.

Which diagnosis most likely explains the clinical features of this patient ?

A :Neuroborreliosis.

B :Neurosarcoidosis.

C : Inflammatory plexopathy.

D : Postherpeticneuralgia.

E : Wartenberg syndrome.

QUESTION #4

A 21-year-old female lost consciousness in a supermarket as she was paying for her shopping. She had hit the cash counter with her head. Her eyes were closed, there were some brief mild clonic jerks in her limbs. There was a pulse rate of 45/min with small pupils. She regained consciousness on the floor within seconds. Before the episode she reported feeling light-headed and dizzy for several seconds. After the episode she promptly felt well although suffering from some headache. She had already experienced numerous similar episodes since adolescence. Her mother is suffering from migraine.

Which diagnosis most likely explains the clinical features of this patient ?

A : Basilar migraine.

B :Cataplexia.

C : Focal epilepsy.

D : Reflex epilepsy.

E : Vasovagal syncope.

QUESTION #5

A 62 year-old watchmaker has had Parkinson's disease for more than 6 years. He is taking a combination therapy of 600 mg L-Dopa and 16 mg ropinirole extended release (ER). His wife mentions that at times of insufficient motor control, her husband takes an additional soluble L-Dopa preparation, which can happen up to six times per day. Lately, he has become obsessed with fixing household equipment which he never completes, and has collected buttons in a vase spending hours sorting them according to colour.

What is this condition called?

A : Dopamine withdrawal syndrome.

B :Impersistence.

C : Impulse contrôle disorder.

D :Punding.

E : Utilization.

QUESTION #6

A 36 year old woman is regularly seeing a cardiologist due to a 3rd degree AV-block discovered after repeated episodes of fainting; other members in her family have the same problem. She is referred to the neurology ward after two attacks of visual blurring. The first occurred one year ago and involved the right eye and symptoms resolved after six weeks. A similar attack occurred in the left eye six months later and resolved after three weeks. On further questioning she describes sensory symptoms two years ago in her left arm for two weeks. Reflexes in her left side were brisker than on the right side. MRI of the brain shows 12 lesions, of which 2 are contrast enhancing.

Which drug should NOT be prescribed in this situation ?

A :Alemtuzumab.

B :Fingolimod.

C :Glatiramer acetate.

D :Mitoxantrone.

E :Natalizumab.

QUESTION #7

An 18-year-old female complained of double and blurred vision when looking to the right. Clinical examination revealed a dissociated nystagmus when looking to the right. The saccades to the right were dysconjugate with impaired adduction of the left eye.

Select the most likely eye movement disorder in this patient.

A :Internuclearophthalmoplegia.

B : Ocular bobbing.

C : Optokinetic nystagmus.

D : Rebound nystagmus.

E : See-saw nystagmus.

QUESTION #8

A 35-year-old male was involved in a minor car accident when returning home after a tennis match, and attended hospital because of not being aware of objects on his left side. There was no head injury but nevertheless he felt a throbbing right occipital headache, with no other symptoms. On clinical examination, two hours after the accident, there was a left hemianopia. Eye movements and pupillary function were normal. Blood pressure was 160/95 mmHg. No abnormalities were found on a cranial CT-scan. He reported previous attacks of severe unilateral pulsatile headache with nausea and photophobia between the ages of 15 and 35 years. The frequency of headache was about once in 6 months, with a duration of up to 24 hours.

Which diagnosis applies best to this case?

A : Internal carotid artery stenosis.

B :Migrainous infarction.

C : Reversible vasoconstriction syndrome.

D : Posterior reversible encephalopathy syndrome.

E : Vertebral arterydissection.